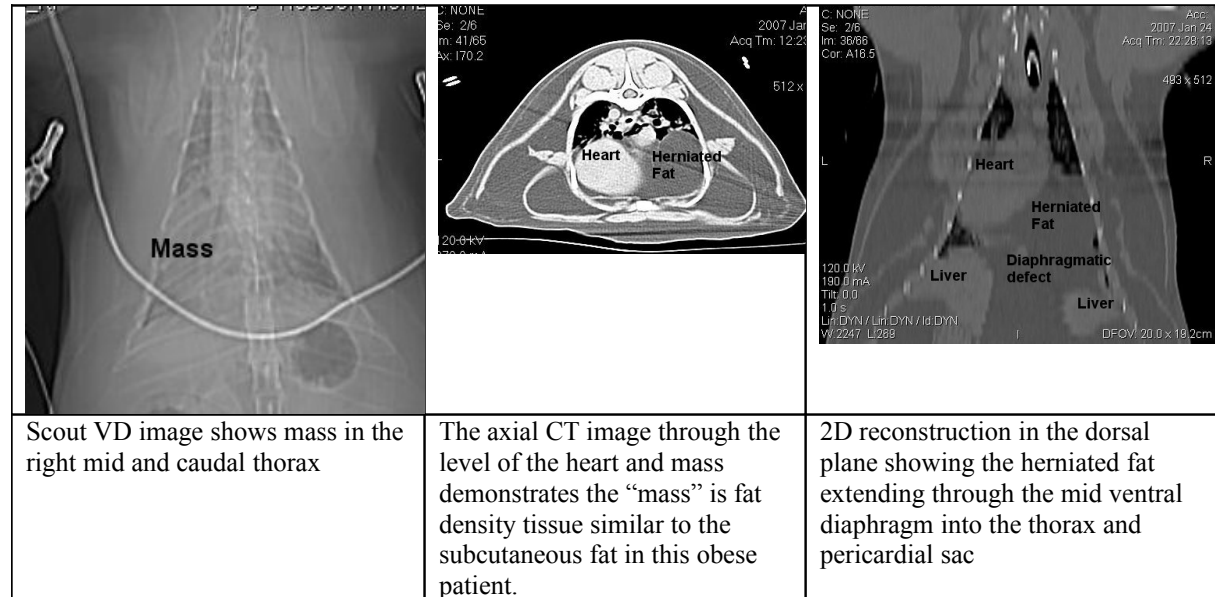


# CT for Dyspnea and Mass lesion

**Case Summary** – A ten year old MN DSH cat presented for one month duration of occasional coughing, lethargy and mild dyspnea. On physical exam the pet was obese. Lung and cardiac sounds were reduced on the right. Survey radiographs revealed a mass in the right mid caudal thorax. Neoplasia, abscess, cyst, granuloma, hematoma and sequestered fluid were considered as possible causes of the mass. A thoracic ultrasound exam was inconclusive.

**Imaging-** A thoracic CT was performed. No complications were encountered and the cat recovered uneventfully. Cross sectional imaging and multiplanar reconstructions of the thorax are shown below.



**Imaging Diagnosis-** Obesity. Pericardioperitoneal diaphragmatic hernia with a large amount of herniated falciform fat creating a mass effect in the right mid and caudal ventral thoracic regions.

**Outcome-** The prognosis is excellent based on the CT diagnosis. The owner elected to have the hernia repaired surgically and the patient did well. Weight loss was also advised.

WWW.VETMRIRT.COM

*CT is the best modality to evaluate thoracic structures.*

*Cross sectional imaging eliminates the uncertainty due to overlapping structures inherent to interpreting radiographs.*

*A rapid helical CT scanner completes thoracic imaging in minutes.*