



Computed Tomography and Surgical Planning

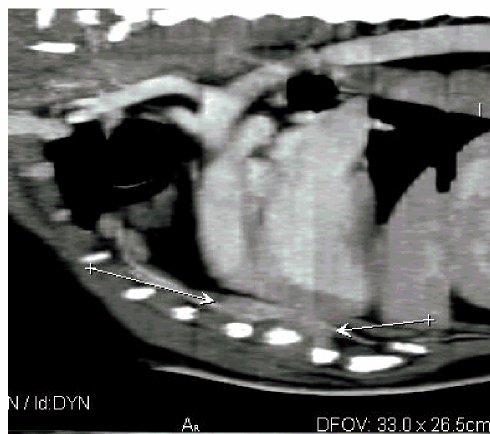
Harlee is a 5 year old, female spayed Doberman Pincher that presented to the Veterinary MRI and Radiotherapy Center for evaluation of a persistent draining tract in the ventral left hemithorax. Approximately 8 months prior to presentation, Harlee sustained a penetrating wound to the left ventral chest. Although not witnessed, several small pieces of bark were removed from the wound on his initial presentation to his local veterinarian.

Over the course of eight months, Harlee had several surgical procedures to clean and explore the wound, however, no additional foreign material was identified.

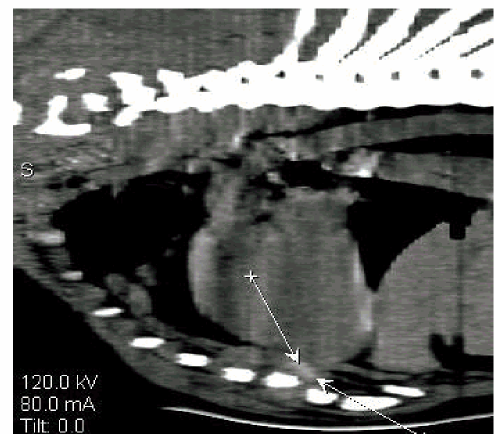
A CT scan was performed to assess for foreign material and the following images were obtained.

Superior soft tissue imaging allows for accurate assessment of pathology.

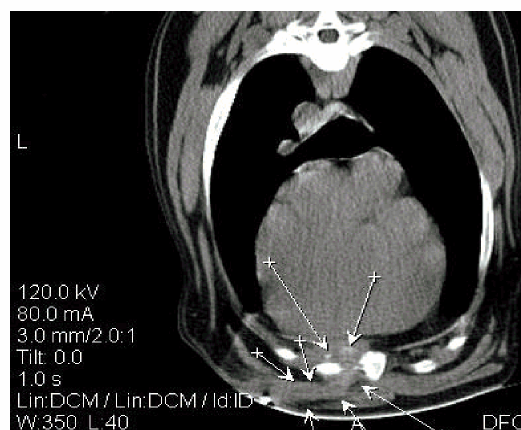
CT allowed for a definitive course of the draining tract identifying the location of the foreign material.



Inflamed tissue dorsal to sternum



Foreign material



Arrows outlining draining tract and foreign material

Discussion

Harlee, following CT examination, had a surgical exploration of the draining tract and a small piece of wood material was removed from the wound (see below). Harlee developed an approximately 3cm abscess one week following surgery which resolved quickly with local wound care and an extended treatment regimen of systemic antibiotics. Harlee has otherwise done well post operatively.



If you have any questions regarding the value of CT or MRI evaluation for a particular patient please do not hesitate to contact our facility to discuss the case prior to requesting an imaging study.

Veterinary MRI and RT Center of NJ
1071 Paulison Avenue
Clifton, NJ 07011
Ph – 973-772-9902
Fax – 973-772-9904

This case report can now be viewed on our website www.vetmirt.com by clicking on the hyperlink “case report” under “for veterinarians”.
